



VCU

Virginia Commonwealth University
VCU Scholars Compass

Theses and Dissertations

Graduate School

2020

The Effects of Exosomes on the Regeneration of Rat Calvaria

Jill T. Beitz

Virginia Commonwealth University

Follow this and additional works at: <https://scholarscompass.vcu.edu/etd>



Part of the [Periodontics and Periodontology Commons](#)

© Jill Beitz

Downloaded from

<https://scholarscompass.vcu.edu/etd/6144>

This Thesis is brought to you for free and open access by the Graduate School at VCU Scholars Compass. It has been accepted for inclusion in Theses and Dissertations by an authorized administrator of VCU Scholars Compass. For more information, please contact libcompass@vcu.edu.

ALL RIGHTS RESERVED

The Effects of Exosomes on the Regeneration of Rat Calvaria

A thesis submitted in partial fulfillment of the requirements for the degree of Master of
Science in Dentistry at Virginia Commonwealth University

by

Dr. Jill Therese Beitz

University of Delaware, B.S. 2010

Virginia Commonwealth University School of Dentistry, D.D.S. 2015

Director: Zhao Lin, B.D.S., M.S., M.M.Sc., Ph.D.

Associate Professor, Department of Periodontics

Virginia Commonwealth University

Richmond, Virginia

April, 2020

Acknowledgements

I would first like to thank my committee – Dr. Zhao Lin, Dr. Thomas Waldrop, Dr. Robert Sabatini, and Dr. Caroline Carrico for generously giving their invaluable time and support to my project. The support of such brilliant and esteemed individuals in their fields was indispensable for maintaining confidence in my work and guiding me throughout my residency in Periodontics. I would like to extend my gratitude to Dr. Lin specifically for the innumerable hours he has dedicated to maintaining an active role in my project, as well as the mentorship he has provided over the last three years.

In addition to my committee, I would like to thank the past members of Dr. Lin’s lab— Andrew Wong, Sonia Talegaonkar, Nick Clayton, and Dr. Sheikh Alam— for assisting during the animal surgeries and providing much-needed guidance in the lab.

Lastly, I would like to thank my significant other and my family for providing me with the infallible support and continuous encouragement throughout the many years of study, as well as through the process of completing this thesis and residency. My accomplishments would not have been possible without them.

Table of Contents

LIST OF FIGURES	IV
ABSTRACT.....	V
INTRODUCTION	1
METHODS	4
RESULTS	7
DISCUSSION	10
CONCLUSION.....	14
REFERENCES	15

List of Figures

Figure 1: Experimental Design.....	3
Figure 2: Surgical Design..	6
Figure 3: Surgical Photos.....	6
Figure 4: 2D Surface Area Analysis.	8
Figure 5: Surface Area Distribution.....	8
Figure 6: Surface Area Distribution.....	9
Figure 7: Volumetric Measurements at Varying Thresholds.....	9

Abstract

THE EFFECTS OF EXOSOMES ON THE REGENERATION OF RAT CALVARIA

By: Jill Beitz, D.D.S.

A thesis submitted in partial fulfillment of the requirements for the degree of Master of Science
in Dentistry at Virginia Commonwealth University

Virginia Commonwealth University, 2020

Thesis Advisor: Zhao Lin, B.D.S., M.S., M.M.Sc., Ph.D.

Associate Professor, Department of Periodontics

Periodontal disease is a bacterial induced chronic inflammatory condition that occurs in a susceptible host, affecting the teeth, gingiva, periodontal ligament, and alveolar bone. The resultant pathological bone defects often require surgical intervention, with the ultimate goal being regeneration of the periodontium through the application of grafting materials and biologics. Mesenchymal stem cells (MSCs) show great potential in regenerative medicine for their ability to enhance cell proliferation and differentiation, increase angiogenesis, and modulate the immune response. Stem cell-derived by-products, known as exosomes are a specific class of lipid-membrane-bound extracellular vesicles that are proliferative and chemotactic, are able to inhibit cytokine production, and may suppress differentiation of osteoclasts. The aim of this

study is to determine if the delivery of exosomes into rat calvarial defects will increase regeneration by reducing the residual defect area and enhancing bone volume. Male Sprague-Dawley rats with bilateral 5mm surgically-created calvarial defects were randomized into groups and treated with low- and high-dose exosome suspensions via a collagen gel matrix or a PBS-soaked collagen control. After 4 weeks, the calvaria were harvested and analyzed via micro computed tomography (micro-CT). Volumetric micro-CT analysis showed that defects treated with high-dose exosomes displayed a trend towards enhanced bone healing. Based on the results of this pilot study, treatment with exosomes could be a promising therapeutic approach for treatment of bone defects.

Key words: Stem cell, exosome, calvarial defect, bone regeneration

Introduction

Periodontal disease is a chronic inflammatory condition that is the result of a bacterial challenge in a susceptible host and affects the teeth, gingiva, periodontal ligament, and alveolar bone. According to a recent CDC report, 46% of adults over 30 in the U.S. have some form of periodontal disease.¹ The aim of initial periodontal therapy is to reduce the bacterial load in the oral cavity through methods of scaling and root planning, however further surgical intervention is often necessary. The ultimate goal of periodontal treatment is the regeneration of the periodontium, which includes the alveolar bone, periodontal ligament, and cementum. Some clinical approaches to achieving regeneration of the periodontium include osseous grafting and guided tissue regeneration (“GTR”). These techniques use a variety of grafts, including autogenic, allogeneic, or xenogeneic bone and often combine them with other modalities such as membranes, and/or biologically active agents, such as enamel matrix derivate and growth-factor enhanced matrix containing platelet derived growth factor (rhPDGF-BB).^{2,3} In non-critically sized periodontal defects, regeneration occurring via the bodies’ own intramembranous and endochondral ossification produces bone with little scar tissue and almost indistinguishable characteristics from surrounding native bone.⁴ In critically sized defects or where natural regeneration is insufficient, clinicians may apply these regenerative techniques to augment bone repair.

Derived from historical practices of tissue engineering and biological scaffolding, cell-based regenerative medicine is drawing progressively more attention in recent years based upon its great potential.⁵ Human mesenchymal stem cells (MSCs) show great promise in regenerative

medicine for their ability to enhance cell proliferation and differentiation, increase angiogenesis, and modulate the immune response. Many of the regenerative properties of MSCs have been demonstrated to be mediated through cell-derived by-products, known as exosomes.⁶ Exosomes are a specific class of lipid-membrane-bound extracellular vesicles, ranging from 40-150nm in diameter. They are produced by many cell types, contain various functional proteins, mRNAs, microRNAs, and lipids, and play a critical role in cell-to-cell communication.⁷ Bioactive molecules are encapsulated in these vesicles and are subsequently transferred to cells in the local environment or distant organs, and may regulate the behavior of recipient cells. Exosome-based therapies in animal models have been shown to promote the regeneration of tissues in various organs, including the heart, kidney, skin, and nervous system by participating in important pathways of development, organogenesis, wound healing, and regeneration.⁸⁻¹¹ Their regenerative potential may also be modulated by the exposure of the originating cell population to external stimuli, such as hypoxia.¹²

Treatment with exosomes has some advantages over delivery of human cells, including resistance to degradation, superior stability and durability, ease of storage, and lower potential for immune rejection, and therefore may represent a generally non-cytotoxic and well-tolerated regenerative therapy.⁶ The specific aim of this study is to determine if the delivery of exosomes into rat calvarial defects will increase regeneration by reducing the residual defect area and enhancing bone volume. This in vivo model consisted of creating 5mm bilateral calvarial defects in male Sprague-Dawley rats, delivering high-dose or low-dose exosomes in collagen gel, or a control gel without exosomes into the defects, and examining the defects after four weeks to evaluate if exosomes exhibited induction of bone formation and promotion of bone healing.

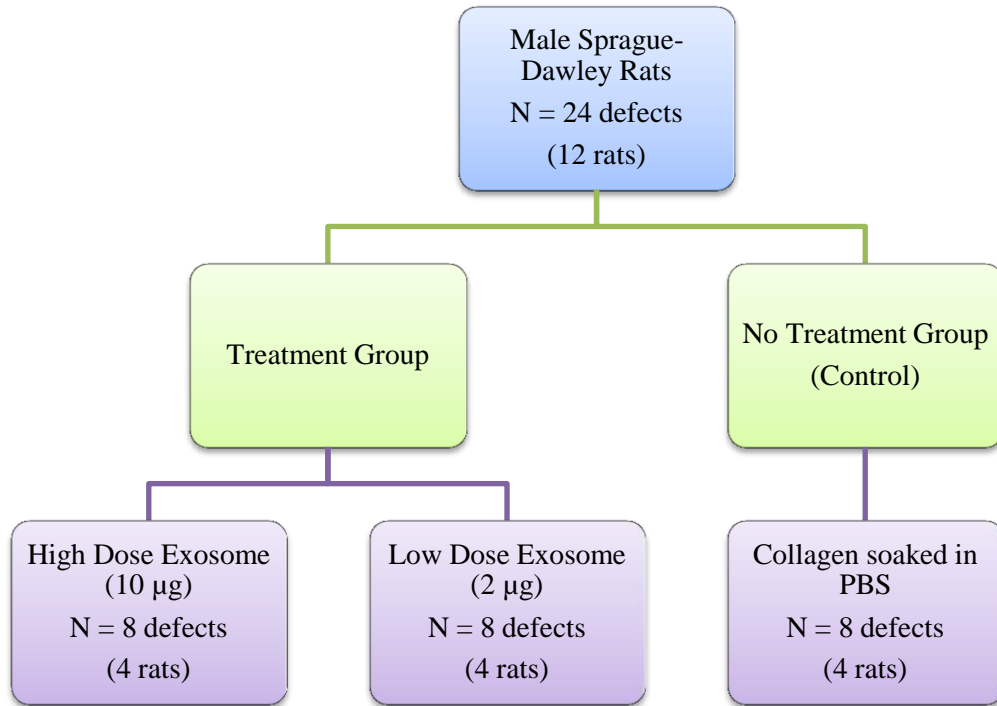


Figure 1: Experimental Design. Flow chart depicting the division of 12 male Sprague-Dawley rats into 24 randomized defects.

Methods

Human bone marrow stromal cells were cultured with exosome-depleted media for 48 hours. The media were collected and exosomes were harvested by sequential ultracentrifugation with the following protocol: cell debris and large cell fragments were removed first at a gravitational force of 500g for 10 minutes; then at 2,000g for 10 minutes; and finally at 10,000g for 30 minutes. Exosomes were then collected at 100,000g for 70 minutes and the pellets were washed in 0.9% NaCl and centrifuged a second time at 100,000g for 70 minutes. The pellets were then re-suspended in phosphate-buffered saline (PBS) and stored at -80°C for the animal experiment.

All procedures performed on animals followed protocols approved by the Institutional Animal Care and Use Committee (IACUC) at Virginia Commonwealth University (Protocol #AD10001541). Twelve male Sprague-Dawley rats (approximately 250 to 300 grams, aged 9 to 10 weeks) were divided into three groups: no treatment (collagen soaked in PBS), high-dose exosome (collagen soaked in 10 μg exosomes), and low-dose exosome (collagen soaked in 2 μg exosomes) (Figure 1). The rats were anesthetized with 4% isoflurane in O₂ for induction and then maintained at 1-3% isoflurane in O₂. A subcutaneous injection of buprenorphine (1.0mg/kg) was used for perioperative analgesia, after which the surgical site was shaved and cleaned with betadine and 70% ethanol. Once the rats were transferred to the heated surgical table and covered with sterile drapes, a linear scalp incision was made from the nasal bone to the occiput, and full-thickness flaps were elevated. The periosteum overlying the calvarial bone was completely reflected.

Trephine burs under copious irrigation were used to create bilateral 5mm craniotomy defects in each rat, centered on each side of the parietal calvarial bone (Figures 2 and 3).

Attention was given to avoid damaging the sagittal suture. The calvarial disks were carefully removed to prevent injury to the underlying dura or brain. The three groups were randomized and defects were implanted with either high-dose (10 µg) or low-dose (2 µg) exosome concentrates in a collagen gel, or a PBS soaked collagen matrix without exosomes to serve as the control. The periosteum was sutured internally with interrupted sutures using 4-0 chromic gut, and the incisions were closed with continuous interlocking sutures using 4-0 chromic gut sutures. The closed surgical sites were cleaned again with betadine, and the rats were recovered from anesthesia on a heating pad. One rat died during surgery from anesthetic complications; however the remaining 11 rats convalesced with no post-operative complications. All rats were sacrificed with carbon dioxide inhalation four weeks after implantation, and the calvaria were harvested and fixed in 10% formalin.

Calvarial bone regeneration was quantified by the use of a Bruker Skyscan 1173 Micro-CT (Billerica, MA). The harvested calvaria were scanned and raw images were generated. The images were examined at thresholds ranging from 110-190 Hounsfield units (Hu) to further exclude immature bone. A region of interest was generated using a cylindrical section with a 5mm radius to encompass the defect area exclusively. The quantification of new bone was established through surface area regrowth percentage and total bone volume in mm³ at a threshold of 110 Hu.

The two-dimensional data depicting surface area distribution was analyzed using Fisher's Exact test to evaluate differences in bone fill between treatment and control groups. Next, the total bone volume in mm³ was analyzed using one-way analysis of variance (ANOVA), followed by Bonferroni's multiple-comparison test. P<0.05 was considered to be statistical significance.

The results were expressed as means \pm standard deviation, and graphs were prepared using Graph Pad Prism 7.02 (Graph Pad Software, CA, USA).

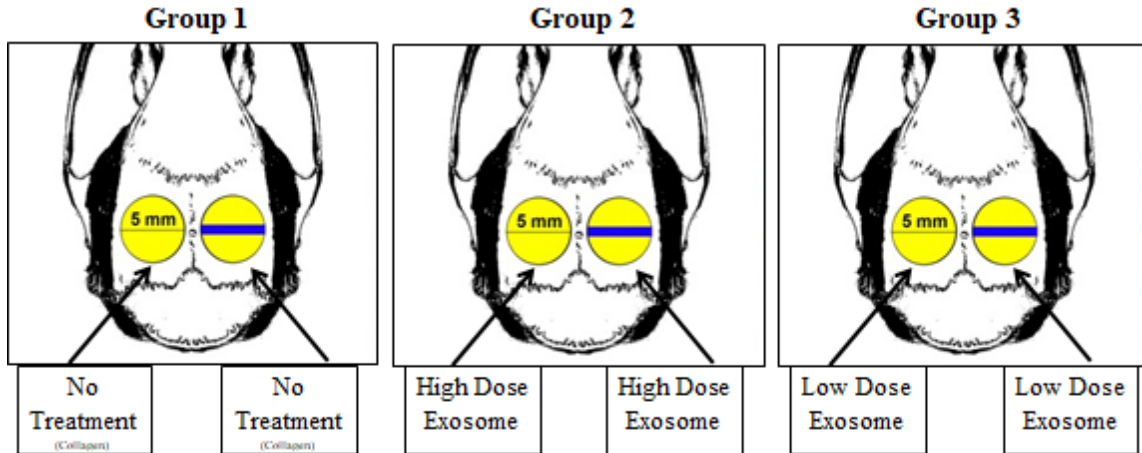


Figure 2: Surgical Design. Rats received one of three possible configurations in both defects. The no treatment group was treated with a PBS-soaked collagen gel vehicle to serve as control. The high-dose exosome treatment group was treated with high-dose (10 μ g) MSC exosome via collagen gel matrix and the low-dose exosome treatment group was treated with low-dose (2 μ g) MSC exosome via collagen gel matrix.

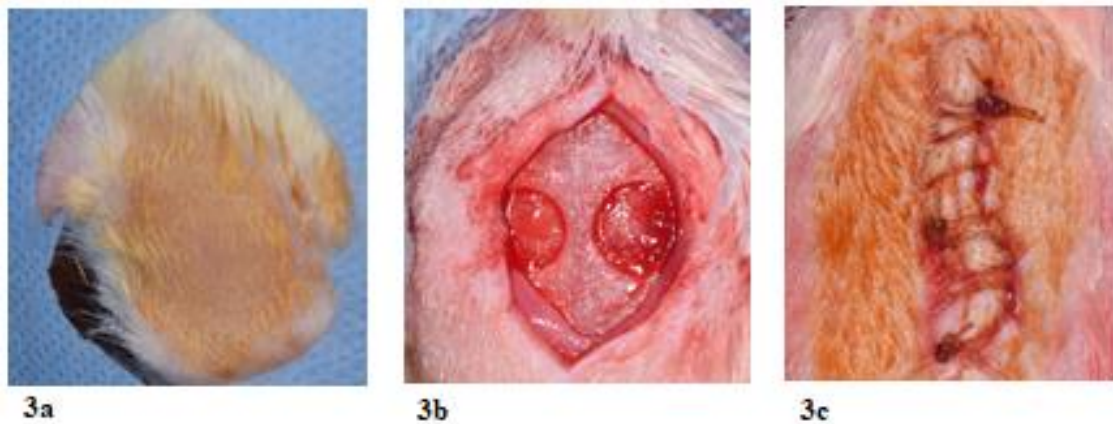


Figure 3: Surgical Photos. a) Pre-operative photo: shaved rat calvaria with sterile drape in place after betadine disinfection. b) Intra-operative photo: split-thickness dissection to access calvaria and 2x 5mm defects surgically created with trephine bur to remove thin disc of calvarial bone while leaving underlying dura matter intact. c) Post-operative photo: primary closure with continuous interlocking sutures with 4-0 chromic gut.

Results

The first parameter measured in this study was the area of defect recovery following different treatment modalities. The results demonstrated a relatively large variance in the area of the defect covered by new bone (Figure 4). Surprisingly, most of the defects resulted in more than 50% recovery. However, when further stratifying the healing into three different categories (<80% recovery, 80-90% recovery, and >90% recovery), collagen soaked in high-dose exosomes led to better bone healing, as evidenced by the finding that 4 out of the 8 defects exhibited greater than 90% recovered surface area. In contrast, this observation was rare in the low-dose exosome group (1 in 6 defects), and in the PBS-soaked collagen control group (0 in 8 defects) (Figure 5). Stratifying the bone fill into three levels failed to achieve statistical significance between the three groups ($p=0.23$). When bone fill was dichotomized into >90% and $\leq 90\%$, however, significance was reached ($p=0.04$), further demonstrating better bone healing in the high-dose exosome group (Figure 6).

Next, bone volume (mm^3) was measured within the defect area. At the threshold of 110 Hu (a standard threshold for bone), it was observed that treatment with the high-dose exosome appears to have higher bone volume than the other groups, although no statistical difference was seen due to the small sample size ($p=0.48$) (Figure 7). When a variety of thresholds were applied to differentiate the maturity of the newly-formed bone, this trend was more prominent as the threshold increased, suggesting that more mature bone was found in the high-dose exosome group. Conversely, the low-dose exosome group did not appear to be much different from the collagen gel control. In addition, there was a larger variance in the high-dose exosome group compared to the control.

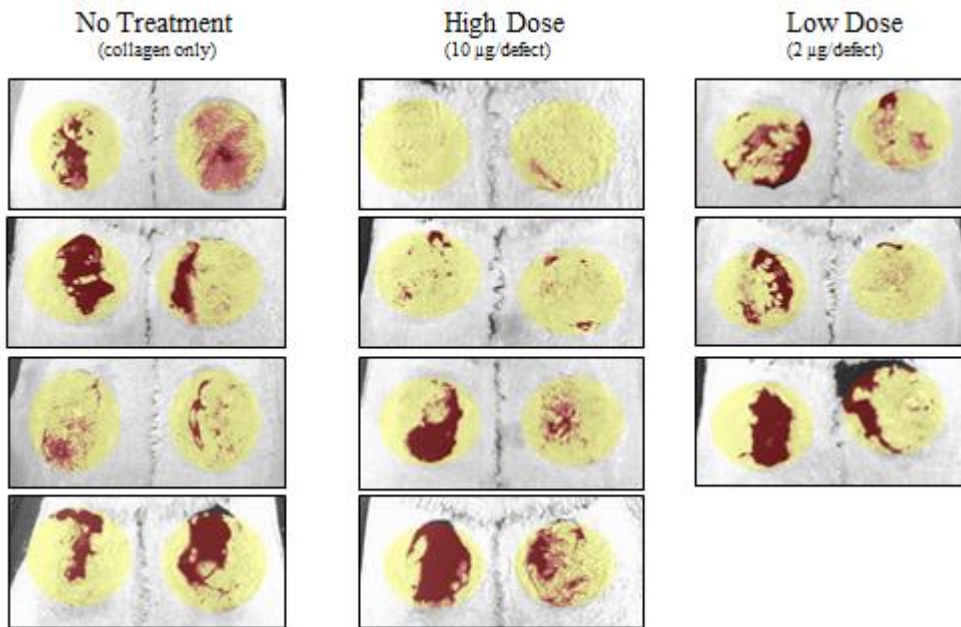


Figure 4: 2D Surface Area Analysis. Surface area analysis comparing the collagen gel control, high-dose exosome, and low-dose exosome groups at a threshold of 180 Hu. The 5mm defect is represented by the circle above, with the bone fill being depicted in yellow and absence of bone (likely soft tissue in-growth) is depicted in red.

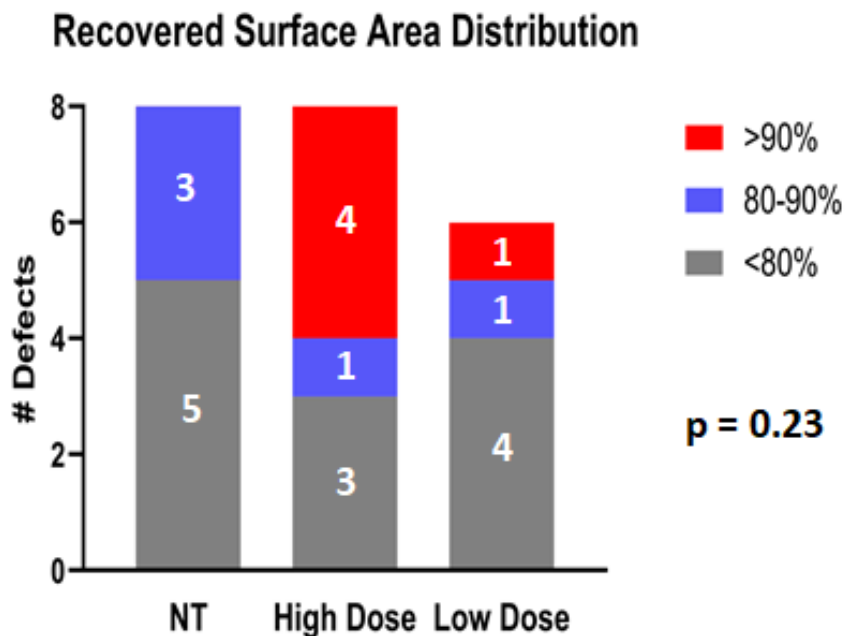


Figure 5: Surface Area Distribution. Bar graphs depicting three parameters of the recovered surface area of bone per number of defects for collagen control, high-dose exosome (10 µg), and low-dose exosome (2 µg) groups

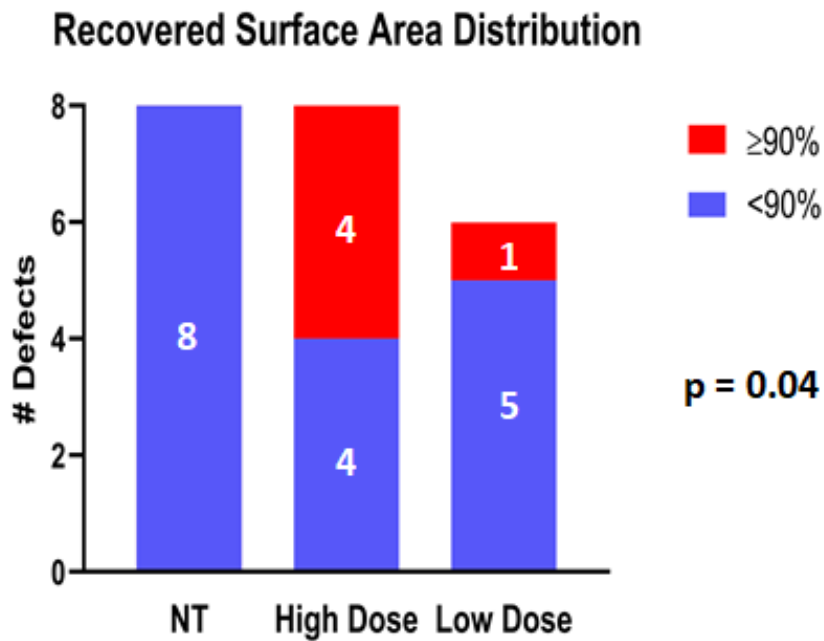


Figure 7: Surface Area Distribution. Bar graphs depicting three parameters of the recovered surface area of bone per number of defects for collagen control, high-dose exosome (10 μg), and low-dose exosome (2 μg) groups

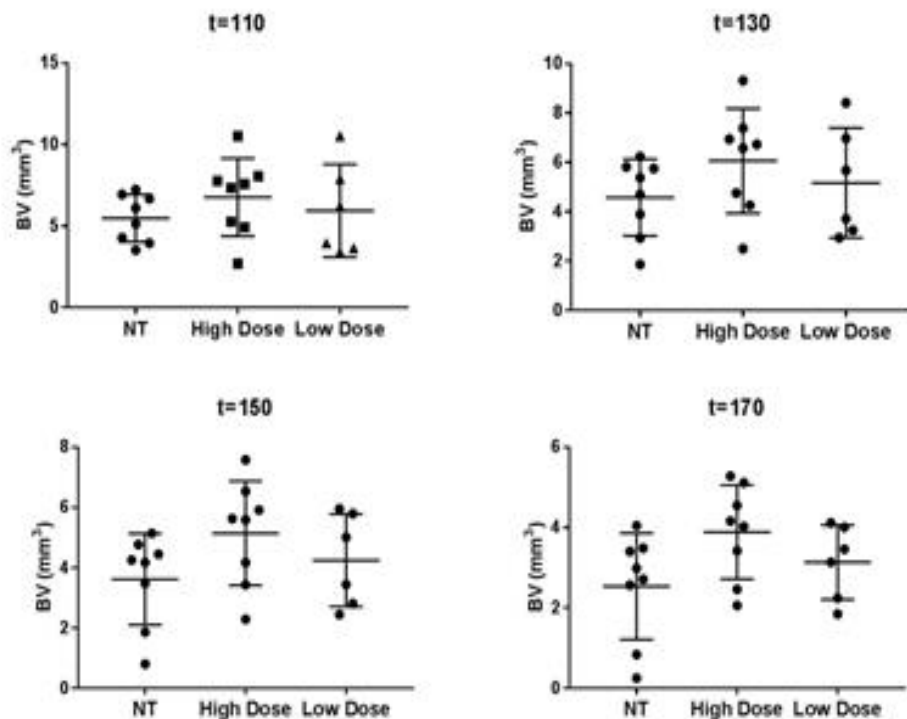


Figure 6: Volumetric Measurements at Varying Thresholds. Scatter plots showing bone volume in mm^3 at thresholds 110, 130, 150, and 170 for collagen control, high-dose exosome (10 μg), and low-dose exosome (2 μg) groups.

Discussion

Bone grafting with autogenous and non-autogenous grafts remains the standard of care in human bone regeneration, but limitations persist, particularly in the recovery time and associated morbidity of the procedure. Human mesenchymal stem cells show great potential in regeneration due to their ability to enhance cell proliferation and differentiation, increase angiogenesis, and modulate the immune response. In this study, more defects treated with high-dose (10 μg) MSC exosomes achieved greater than 90% surface recovery as compared to the low-dose (2 μg) and control groups. As assessed using 3-D measurement, greater bone volume overall was seen in the high-dose exosome group, although this was not statistically significant ($p=0.48$). When the thresholds for bone tissue were adjusted, the differences between the high-dose group and control group appeared to be greater, suggesting that exosome treatment may be associated with more mature bone formation. The four-week time period of this study, however, may have been too short. At four weeks, most of the regenerated bone may have consisted of woven, or immature, bone.^{13,14} This is based on the knowledge that it takes approximately 38 days to for a human extraction socket to become 2/3 filled with trabecular bone, and human intra-bony defects can take anywhere from 2-3 months to heal completely, based on histologic evidence.¹⁵ Thus, longer time points may help us better understand the potential effects of exosomes on the maturation bony defects.

Many defect healing studies use bone volume recovery as a benchmark for healing, however volume recovery measurements alone do not adequately explain the nature of the bone healing that occurs in this model. The geographic pattern of new bone formation in these defects is another important consideration that may contribute to understanding bone healing. In critical size defect models, center healing is typically considered the most difficult to achieve and may

be a valuable benchmark for measuring defect healing with full-width viewing. In this study, data from a side by side comparison of the high-dose and low-dose exosome groups versus the collagen control group indicated that more defects treated with exosomes exhibited coverage at the center of the circular defects than those in the collagen group (Figure 4). In a separate but similar study, the 5mm circular calvarial defect was treated with high-dose exosomes or a collagen gel control. A more in-depth micro-CT examination of the defects was performed. In this case, the 5mm defects were examined at sequentially smaller disc-shaped zones of 4, 3, 2, and 1mm diameters that originated from the defect center to investigate bone regeneration patterns.¹⁶ This division was done with the knowledge that the defect center, which is the furthest point away from the scaffold of native bone, is typically the most challenging area to treat. When the defect area was separated into these smaller zones, a pattern of enhanced bone healing appeared towards the center of the defect, and greater regeneration was observed in the exosome groups as compared to the collagen groups, with this difference becoming greater with increased proximity to the defect center. Those findings were consistent with what was observed in this study.

Several studies have been published that document the benefits of exosomes and the potential applications of exosome therapy in dentistry. A study by Chew et al in 2019 examined the effects of human MSC exosome-loaded collagen sponge on periodontal regeneration of surgically created intrabony defects in an immunocompetent rat model.¹⁷ The defects treated with collagen sponges loaded with exosomes showed a reduction in the size of the bone defect in comparison to the collagen sponge alone and untreated groups. Exosome-treated rats had more effective repair of the defects with regeneration of newly formed bone and periodontal ligament.

It was concluded that exosomes enhanced regeneration through increased cellular migration, proliferation, synthesis, and differentiation into new bone and PDL.

Qi et al measured the effect of critical size calvarial defects in Sprague-Dawley rats treated with β -TCP loaded with high-dose or low-dose exosomes as compared to β -TCP alone.⁷ Similar to the trend observed in this study, the β -TCP group treated with high-dose exosome exhibited more newly formed bone and higher bone density. Additionally, both the high-dose and low-dose exosome β -TCP groups showed increased neo-angiogenesis as compared to β -TCP treatment alone. In another study, Liang et al examined the effects of pretreating stem cells with Dimethylxaloylglycine (DMOG), a molecule that inhibits the ability of prolyl hydroxylase to regulate the stability of HIF-1 α , thereby mimicking hypoxia in cells under normal oxygen levels.¹⁸ Based on the knowledge that exposure to oxidative stress induces the expression of proangiogenic proteins, that study examined the effects of treatment with DMOG on increased angiogenesis and bone regeneration in a critical size calvarial defect rat model. The results of the study demonstrated more newly formed bone in the DMOG treated exosome group, markedly higher new bone volume relative to tissue volume, and greater neovascularization. In summary, the addition of DMOG to MSC exosomes is a promising pretreatment for exosome-based approaches to treating bone defects.

Mohammed studied the effects of using exosomes as an adjunct to nonsurgical periodontal therapy versus scaling and root planing alone in a rat ligature model.¹⁹ The authors found that the exosome group exhibited the least amount of inflammatory infiltrate and demonstrated signs of new periodontal tissue formation at two days. At two weeks, the exosome group showed the greatest degree of proliferation in periodontal tissues with increased cellularity and organization, and at four weeks the exosome group showed the most significant signs of

healing. Based on these results, adjunctive exosome treatment is a promising regenerative technique to enhance therapeutic outcomes of nonsurgical periodontal therapy.

The results of the current study are in line with aforementioned observations. The primary aim of this pilot study was to determine the appropriate dose of exosomes in future calvarial defect model studies. Power analysis was conducted based on preliminary results and if the volume of newly-formed bone is used as the primary outcome, achieving a level of statistical significance in future studies would require a sample size of 11 per group to achieve a type I error rate of less than 5%, given the same defect size and with sufficient power (80%). Similarly, because there was not a large difference between the low-dose exosome group and the collagen control group, future studies may be conducted to compare only two groups, the high-dose exosome group and the collagen group while also incorporating a negative or empty control. Another possibility for future studies would be to use Sprague-Dawley rats that are older. In this study the rats were between 9 and 10 weeks old, at which point they exhibit a very strong natural growth ability and regenerative potential. This may imply that older rats be used in future studies to minimize the effects of the strong natural regenerative potential observed in younger rats.

Finally, one may question whether the defects created in this study were truly critical size defects. By definition, a critical size defect is one that will not fully regenerate in the natural lifetime of the animal.²⁰ While some studies propose that the 5mm defect is critically sized, others advocate for an 8mm critical defect in rat calvaria.²¹ In this study, the natural regenerative potential in the collagen control groups after only four weeks of healing indicates that the defect model in this study is not critically sized. In the future, larger defects should be considered.

Conclusion

Defects treated with high-dose MSC exosomes demonstrated a trend towards enhanced healing, structural integrity, and growth uniformity in a calvarial defect model. Based on the results of this pilot study, treatment with MSC exosomes could be a promising therapeutic approach for treatment of bone defects.

References

1. Eke PI, Dye BA, Wei L, et al. Update on prevalence of periodontitis in adults in the United States: NHANES 2009 to 2012. *J Periodontol* 2015;86(5):611–622.
2. American Academy of Periodontology. Position Paper: Periodontal Regeneration. *J Periodontol* 2005;76(9):1601–1622.
3. Ivanovski S. Periodontal regeneration. *Aust Dent J* 2009;54(s1):s118–s128.
4. Einhorn TA. The cell and molecular biology of fracture healing. *Clin Orthop Relat Res* 1998;355(s):s7–21.
5. Mason C, Dunhill P. A brief definition of regenerative medicine. *Regen Med* 2008;3(1):1–5.
6. Basu J, Ludlow JW. Exosomes for repair, regeneration and rejuvenation. *Expert Opin Biol Ther* 2016;16(4):489–506.
7. Qi X, Zhang J, Yuan H, et al. Exosomes secreted by human-induced pluripotent stem cell-derived mesenchymal stem cells repair critical-sized bone defects through enhanced angiogenesis and osteogenesis in osteoporotic rats. *Int J Biol Sci* 2016;12(7):836–849.
8. Dorronsoro A, Robbins PD. Regenerating the injured kidney with human umbilical cord mesenchymal stem cell-derived exosomes. *Stem Cell Res Ther* 2013;4(2):8–10.
9. Choi JS, Yoon HI, Lee KS, et al. Exosomes from differentiating human skeletal muscle cells trigger myogenesis of stem cells and provide biochemical cues for skeletal muscle regeneration. *J Control Release* 2016;222:107–15.
10. Tan CY, Lai RC, Wong W, Dan YY, Lim SK, Ho HK. Mesenchymal stem cell-derived exosomes promote hepatic regeneration in drug-induced liver injury models. *Stem Cell Res Ther* 2014;5(3):1–14.
11. Ibrahim AGE, Cheng K, Marbán E. Exosomes as critical agents of cardiac regeneration triggered by cell therapy. *Stem Cell Reports* 2014;2(5):606–619.
12. Zhang HC, Liu X Bin, Huang S, et al. Microvesicles derived from human umbilical cord mesenchymal stem cells stimulated by hypoxia promote angiogenesis both in vitro and in vivo. *Stem Cells Dev* 2012;21(18):3289–3297.
13. Boyne PJ. Osseous repair of the postextraction alveolus in man. *Oral Surg Oral Med Oral Pathol* 1966;21(6):805–813.
14. Amler MH. The time sequence of tissue regeneration in human extraction wounds. *Oral Surg Oral Med Oral Pathol* 1969; 27: 309–138.
15. Drago MR, Sullivan HC. A clinical and histological evaluation of autogenous iliac bone grafts in humans. I. Wound healing 2 to 8 months. *J Periodontol* 1973;44(10):599–613.

16. Wong AP. Regenerative potential of mesenchymal stem cell derived exosomes. [Thesis]. Richmond, VA: Virginia Commonwealth University; 2019; 72 p.
17. Chew JRJ, Chuah SJ, Teo KYW, et al. Mesenchymal stem cell exosomes enhance periodontal ligament cell functions and promote periodontal regeneration. *Acta Biomater* 2019;89:252–264.
18. Liang B, Liang JM, Ding JN, Xu J, Xu JG, Chai YM. Dimethyloxaloylglycine-stimulated human bone marrow mesenchymal stem cell-derived exosomes enhance bone regeneration through angiogenesis by targeting the AKT/mTOR pathway. *Stem Cell Res Ther* 2019;10(1):1–11.
19. Mohammed E, Khalil E, Sabry D. Effect of adipose-derived stem cells and their exo as adjunctive therapy to nonsurgical periodontal treatment: A histologic and histomorphometric study in rats. *Biomolecules* 2018;8(4):167.
20. Schmitz JP, Hollinger JO. The critical size defect as an experimental model for craniomandibulofacial nonunions. *Clin Orthop Relat Res* 1986;205:299–308.
21. Spicer PP, Kretlow JD, Young S, Jansen JA, Kurtis Kasper F, Mikos AG. Evaluation of bone regeneration using the rat critical size calvarial defect. *Nat Protoc* 2012; 7(10): 1918–1929.